

## Key Points

Exploratory laparotomy or operative laparoscopy is required for solid adnexal masses. The histology should be determined intraoperatively. If a malignancy is found it should be decided if staging is required.

For children and adolescents with a unilateral malignancy, a unilateral oophorectomy or salpingo-oophorectomy and staging (when indicated) is appropriate. The histologic type and stage determines the need for adjuvant chemotherapy.

Serum markers (HCG, AFP, LDH for germ cell tumors; estradiol, testosterone, CA 19-9, and inhibin A and B for sex-cord stromal tumors and CA-125 for epithelial tumors) should be obtained prior to surgery, and if positive, followed.



CHILDHOOD GYNECOLOGIC  
CANCER ASSOCIATION

[www.cgynca.org](http://www.cgynca.org)

## Ovarian Cancer in Children and Adolescents



The Childhood Gynecologic  
Cancer Association (CGYNCA)  
Post Office Box 3130  
Ann Arbor, Michigan 48106-3130

Phone: 734-663-7251  
E-mail: [hope@cgynca.org](mailto:hope@cgynca.org)



Tel: 734 663-7251

Childhood Gynecologic Cancer Association is a registered 501(c)3 non-profit organization interested in helping patients and families affected by vulvar, vaginal, cervical, uterine or ovarian cancer.

Education is of utmost importance, for patients and families as well as for health care providers.

#### Executive Director

Hope Haefner, MD

#### Members of the Board

Carolyn Johnston, MD

David Gershenson, MD

Barbara Getty, NP

### Keeping the Spirit of Hope Alive



## OVARIAN CANCER

Approximately 70 percent of malignant ovarian tumors in children are germ cell tumors, 25% are epithelial tumors and 5% are sex-cord stromal tumors. The overall 5 year survival in a recent study was 91.7% and the 10 year survival was 91.4%. There are seven categories of malignant germ cell tumors. These include immature teratomas, dysgerminomas, endodermal sinus tumors, embryonal cell carcinomas, choriocarcinomas, polyembryomas, and mixed germ cell tumors.

#### **SYMPTOMS INCLUDE:**

Pelvic fullness

Pain

Urinary frequency

Dysuria

Digestive complaints (dyspepsia and early satiety)

Acute pain (ovarian torsion)

#### **TREATMENT FOR MALIGNANT GERM CELL TUMORS OF THE OVARY**

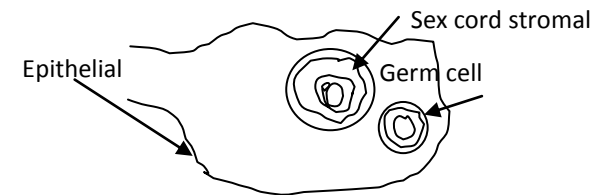
If one ovary is involved, a unilateral oophorectomy versus salpingo-oophorectomy with staging (if indicated) is performed. Dependent on the age of the child, consider consultation with a gynecologic oncologist. The malignant ovary and the fallopian tube on the same side are removed, leaving the uterus, ovary, and fallopian tube on the opposite side in place as long as only one ovary is affected. Staging surgery with the addition of chemotherapy at times (generally bleomycin, etoposide and cisplatin) is the usual treatment. Dysgerminomas are very sensitive to chemotherapy. At times they are treated with carboplatin and etoposide alone.

If both ovaries are involved with tumor, requiring removal, the uterus can be left in place to allow future in-vitro fertilization.

Markers for germ cell tumors should be sent prior to surgery including human chorionic gonadotropin (HCG), alpha-fetoprotein (AFP), and/or lactate dehydrogenase (LDH). If any of the markers are elevated before treatment starts, they are rechecked during chemotherapy. If the chemotherapy is working, the levels will go down to normal. If the levels stay up, it can be a sign that a different treatment is needed.

The other ovarian cancers that occur in children and adolescents are less common. These include: Sex cord stromal tumors: granulosa cell, Sertoli-Leydig cell, gynandroblastoma. Markers for this tumor category consist of estradiol, testosterone, CA 19-9, and inhibin A and B.

Epithelial tumors (including ovarian tumors of low malignant potential):serous, mucinous, endometriod, clear cell, transitional cell, Brenner, carcinosarcoma, and undifferentiated tumors. CA-125 is a marker for these tumors.



**The Childhood Gynecologic  
Cancer Association (CGYNCA)  
Post Office Box 3130**

Phone: 734-663-7251

E-mail: [hope@cgynca.org](mailto:hope@cgynca.org)